

Association of Histological Grading of Oral Submucous Fibrosis to Cytokeratin 19 Immunohistochemical Staining

DR SHAN NAWAZ MALIK¹, DR ZANKANA VYAS², DR HEMANTH KOTARI³,
DR. VISHNUDAS DINESH PRABHU⁴, DR MARIYAM SHAHINA K E⁵

¹ PhD student, Pacific university, Udaipur, Rajasthan, India

² Professor, Pacific Dental College, Udaipur, Rajasthan, India

³ Dean & Professor, Pacific university, Udaipur, Rajasthan, India

⁴ Professor and Head, Department of Oral and Maxillofacial Pathology, Yenepoya dental college, Yenepoya University, Mangalore, India

⁵ St Johns Medical College, Bangalore, Karnataka, India

Email - Shanawaz_mlk@yahoo.com, zankhana.dr@gmail.com, deanpg@pacific-university.ac.in,
drvishnudas@gmail.com, shahina_ke@yahoo.co.in

Abstract: The histological grading of oral submucous fibrosis has been made as grade 1,2 and 3 according to severity of fibrosis and hyalinization but the intensity of immunohistochemical staining of cytokeratin 19 has not been done to analyse and establish the fact whether the intensity increases according to histologic severity. 35 cases of oral submucous fibrosis were histologically graded and immunohistochemical study was done using cytokeratin 19. Among 35 cases 8 cases of grade 1 showed 12.5% of negative, 12.5% of mild, 50% of moderate and 25% of intense staining. 14 cases of Grade 2 showed 0% of negative, 64.2% of mild, 21.4% of moderate and 14.2% of intense staining. 13 cases of Grade 3 showed 0% negative, 23% mild, 46.1% moderate and 30.7% intense staining. Since the overall and comparative P values were insignificant, cytokeratin 19 staining alone cannot be used as a surrogate marker to check the severity and transformation of oral submucous fibrosis to malignancy in different histologic grades of oral submucous fibrosis.

Key Words: Cytokeratin 19(CK19), oral submucous fibrosis (OSF), immunohistochemistry (IHC), squamous cell carcinoma (SCC), normal oral Mucosa (NOM)

1. INTRODUCTION:

OSF is one of the most commonest potentially malignant disorders, previously called as premalignant condition. The study provides a detailed interaction between OSF and cytokeratin 19 based on the histological grades of OSF.

Recently, various Immunohistochemical markers are showing great promise in helping to predict prognosis and response therapy, even at a very early point of tumor development or may it be a premalignant condition like OSF¹. Alteration of CK19 expression has been documented in leukoplakia and oral cancer² The present study is carried out to characterize the CK19 profile in OSF based on the histological grades of OSF and ascertain if this could be used as a surrogate marker for malignant transformation and if the results hold positive then cytokeratin 19 can be the ideal surrogate marker that can be used to analyze and characterize the rate and conversion of OSF to oral squamous cell carcinoma or any malignant lesion correlating it with histological grading of OSF.

2. MATERIALS AND METHODS:

Hypotheses to be tested:

Whether cytokeratin-19 can be used as a surrogate marker for malignant transformation of oral submucous fibrosis based on whether the intensity increases according to histologic severity.

Source of data:

Total of 35 cases of oral submucos fibrosis was taken for the study.

Confirmed Oral submucos fibrosis was taken for this study and was collected from department archives and the patients attending the department of oral medicine, oral surgery and other departments of Yenepoya Dental College, Mangalore.

They were histologically divided based on fibrosis and hyalinization into

Grade I:

Loose, thick and thin fibers

Grade II:

Loose or thick fibers with partial hyalinization.

Grade III:
Complete hyalinization³

3. SAMPLE SIZE:

35 cases of histologically confirmed cases of oral sub mucous fibrosis were included and sections of size less than 2µm were excluded.

Collection of data

Sections of 3µm thickness were prepared from the formalin fixed, paraffin embedded tissue blocks. The sections were mounted on poly L-lysine coated slides for cytokeratin 19 expression the staining was done immunohistochemically using polymerase technique, the primary and secondary antibody for the study was obtained from Biogenex, Bangalore.

All the sections were coded before staining for CK-19, Evaluation of cytokeratin 19 was done under light microscope under 10× objective and the intensity of staining of epithelium was assessed as (-) negative, (+) mild, (++) moderate, (+++) intense, the sections were decoded and results tabulated¹.

The intensity of staining was analyzed by the percentage of tissue section stained per slide.

If no tissue is stained	- Negative
If 1/3 of the epithelium tissue is stained (approximately 33%)	- Mild
If 2/3 of the epithelium tissue is stained (approximately 66%)	- Moderate
If more than 2/3 of the epithelium tissue is stained (above 66%)	-Intense ¹ .

Two independent observers evaluated the slides when discrepancy existed a third pathologist was asked to evaluate the slide to arrive at the consensus conclusion, 35 cases of oral submucos fibrosis section were analysed after dividing them based on grade as grade 1, 2 and 3 respectively. A total of 35 sections altogether were analysed.

Statistical Analysis:

The results were calculated using Fisher's Exact test. All statistical analyses were done using STATA 14. P value less than 0.05 was considered statistically significant.

Photomicrographs were obtained using CX-(Olympus) microscope

4. RESULTS

Out of 35 cases of OSF, 8 cases were grade 1, 14 cases were grade 2 and 13 cases were grade 3.

8 cases of grade 1 showed 12.5% of negative, 12.5% of mild, 50% of moderate and 25% of intense staining. Grade 2 showed 0% of negative, 64.2% of mild, 21.4% of moderate and 14.2% of intense staining. Grade 3 showed 0% negative, 23% mild, 46.1% moderate and 30.7% intense staining represented in table 1.

After Fisher's Exact test The P value = 0.136ns. Since the total P value is 0.136ns and

Grade 1 vs grade 2	0.096
Grade 1 vs grade 3	1.000
Grade 2 vs grade 3	0.105

There is no significant difference between the intensity levels and were not considered statistically insignificant.

5. DISCUSSION:

Oral potentially malignant disorder (OPMD) is a common term suggested to replace oral pre-cancer, including both oral precancerous lesions and oral precancerous conditions. All oral lesions that carry a risk of malignant transformation are included under this term. Oral submucos fibrosis is one of the oral potentially malignant disorders⁴.

Oral sub mucous fibrosis (OSF) is a chronic, progressive scarring disease, which predominantly affects the people of south- East Asian origin⁵.

The early signs and symptoms of this disorder are intolerance to spicy food, altered salivation, ulceration, vesiculation, pigmentation changes, recurrent stomatitis and petechiae. Extra orally, there may be loss of pigmentation or excessive pigmentation of vermillion borders in some of the cases⁶.

The buccal mucosa, retro molar area and soft palate are the most commonly affected sites. The mucosa in this region develops a blotchy, marble – like pallor and a progressive stiffness of sub epithelial tissues⁷.

Clinically OSF cases can be categorized into three clinical stages according to their ability to open the mouth, as given below.

Stage I – Mouth opening \geq 45 mm

Stage II – Restricted mouth opening 20- 44mm

Stage III – mouth opening \leq 20mm⁸

A vivo study on mouse model for study of development of oral sub mucous fibrosis by Sumetha Perera showed the areca- nut treated oral epithelium showed progressive changes in epithelial thickness leading to atrophy, increased cellularity of fibroblasts, fibrosis of connective tissue, focal infiltration of inflammatory cells and muscle atrophy⁹

Histologically OSF can be grouped into four clearly definable stages: very early, early, moderately advanced and advanced. These stages are based on nature of the sub epithelial collagen, presence or absence of edema, physical state of the mucosal collagen, overall fibroblastic response state of blood vessels and predominant cell type in the inflammatory exudate. The connective tissue in advanced state is characterized by the sub mucosal deposition of extremely dense and a vascular collagenous tissue with variable numbers of chronic inflammatory cells⁴.

Kiran Kumar et al (2007) proposed histological grading as follows:

Grade I:

Loose, thick and thin fibers

Grade II:

Loose or thick fibers with partial hyalinization.

Grade III:

Complete hyalinization¹⁰

All epithelial tissues have cytokeratin in them and potentially malignant disorders like OSF have epithelial component

Cytokeratin's that form the cytoskeletons of the epithelial cells are of several molecular types. The patterns of expression of these different types of CKs vary depending upon the type of epithelial cells and hence, they may be used as potential markers of cell differentiation and malignant transformation. CK 19, a type I (acidic) keratin, is the smallest keratin and is unique in that it lacks the Carboxyterminal, non - α - helical tail domain, which is typical for all other keratins¹¹.

In a study done by Ali Yousif et al Expressional profile of both markers (p16 and CK19) was different in same tumour. CK19 positivity was associated with age whereas p16 showed insignificant expression. The expression of p16 decreased while CK19 increased with the tumour grade. This finding also shows that progressive loss of p16 and high expression of CK19 according to tumor metastasis. When p16 and CK19 evaluated together may have more accurate prediction of clinical outcome/prognostic marker in human OSCC and important molecular event in pathogenesis of oral carcinoma¹²

Anand Lalli, in his IHC study observed an increase of KI and K10 in the suprabasal layer, induction of K6 in the basal layer and completes loss of K19 in the epithelium. In a subset of the most severe OSF cases (14%), K17 expression was completely lost in the basal layer which might define them to be at most risk to undergo malignant transformation. There was no detectable expression of K8, K18, K7 and K9 and the expression of K4, K13, K14, K15 and K16 did not change in OSF¹³.

In an IHC study by W.M. Tilakaratne, the data indicated that (hypoxia inducible factor) HIF-1 α is up regulated at both protein and mRNA levels in OSF and the correlation with dysplasia is statistically significant. HIF - 1 α may play a role in malignant transformation of OSF. Further over expression of HIF - 1 α may contribute to the progression of fibrosis. It may be possible to use HIF - 1 α as a marker for malignant transformation of OSF¹⁴

Unlike our study, an IHC study by K. Ranganathan, Significant difference in the CK staining pattern was seen between normal, OSF and cancer. Significant changes in OSF included increased intensity of staining for (Pan Cytokeratin) panCK and (high molecular weight cytokeratin) HMWCK, aberrant expression of CK8 and decreased expression of CKs 5 and 14².

Our study showed a total of 1 negative, 13 mild, 13 moderate and 8 intense staining out of 35 cases. Among 35 cases 8 cases of grade 1 showed 12.5% of negative, 12.5% of mild, 50% of moderate and 25% of intense staining. Grade 2 showed 0% of negative, 64.2% of mild, 21.4% of moderate and 14.2% of intense staining. Grade 3 showed 0% negative, 23% mild, 46.1% moderate and 30.7% intense staining

6. CONCLUSION:

Though few studies have shown that pancytokeratins can be used as a surrogate marker, In our study, there was no significant difference between the intensity levels of OSF among 3 histological grades, hence, this study showed that CK19 profile alone cannot be used to ascertain if it could be used as a surrogate marker for malignant transformation of OSF. Hence our study says that that ck-19 does not play a significant role alone in the transformation of Oral Sub mucous fibrosis to oral. More IHC studies have to be done on different cytokeratin individually to explore a wider diagnostic usage in future.

REFERENCES:

1. Shan Nawaz Malik, Mohammad Khursheed Alam. Cytokeratin-14 Expression in Normal Oral Mucosal Tissue, Oral Submucos Fibrosis and Oral Squamous Cell Carcinoma: An Immunohistochemical Study. International Medical Journal. 2014; 21: 223 – 225.
2. Ranganathan K, Kavitha R. Cytokeratin expression in oral submucos fibrosis- an Immunohistochemical study. J oral pathol med. 2006; 35:25-32.
3. Kumar K, Saraswathi TR et al. Oral sub mucous Fibrosis: A clino-histopathological study in Chennai. Indian journal of dental research. 2007; 18:106-111.
4. Sam Prasad prabhakaran, Arvind muthukrishnan.Expression of cytokeratin 18 and 19 in potentially malignant disorders: a systemic review, journal of Indian academy oral medicine and radiology. 2014; 26:173-177.
5. Shafer WG, Hine MK et al.A Textbook of Oral Pathology Fifth edition, Saunders Company.2007; 136-141.
6. Saraf S, Gandal R et al. Textbook of oral pathology First edition, Jaypee Medical Publishers. 2006; 242-246.
7. Neville BW, Damm DD et al. Oral & Maxillofacial Pathology, Saunders Company.1995; Page 291.
8. Kumar K, Saraswathi TR et al. Oral sub mucous Fibrosis: A clino-histopathological study in Chennai. Indian journal of dental research. 2007; 18:106-111.
9. Perera MWS, Gun singhe D et al. Development of an in vivo mouse model to study oral submucos fibrosis. Oral pathol med. 2007; 36: 273-80.
10. Kumar Kiran. Sarasvathi TR, Rangnathan K. Devi Lima M, Elizabeth Joshua. Oral submucous fibrosis: A clinico- histopathological study in Chennai. Indian Journal of Denial Research 2007;18(3): 106-11.
11. Kamath K P, vidya M. Cytokeratin 19 expression patterns of dentigerous cysts and odontogenic keratocysts, Annals of medical and health sciences research. 2015; 5:119-123.
12. Ali Yousif babiker, Arshad A rehmani et al. Expression analysis of p16 and cytokeratin 19 protein in the genesis of oral squamous cell carcinoma patients. Int J Clin Exp Med.2014; 7(6)1524-1530.
13. Lalli A, Tilakaratne WM. An altered keratinocyte phenotype in oral sub mucous fibrosis; correlation of keratin K17 expression with disease severity. J of oral pathol med. 2008; 37:211-220.
14. Tilakaratne WM, Iqbal Z et al. Up regulation of HIF-1 α in malignant transformation of oral sub mucous fibrosis. J of oral pathol med. 2008; 37:372-377.

AUTHOR'S BIOGRAPHY:

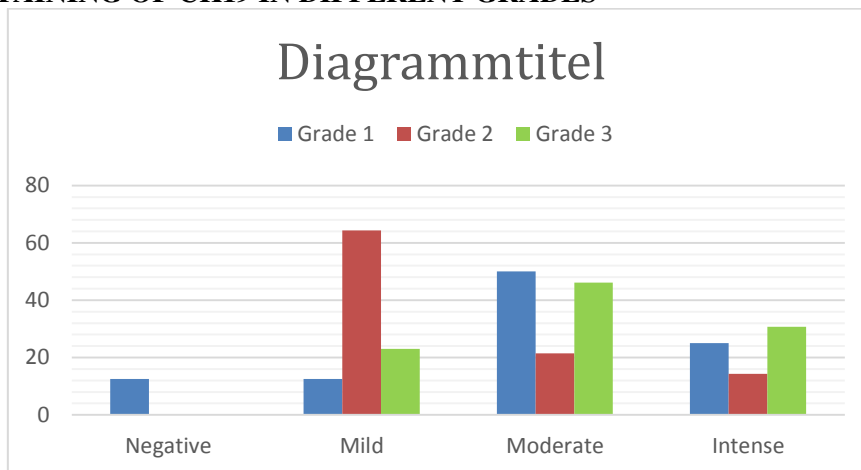
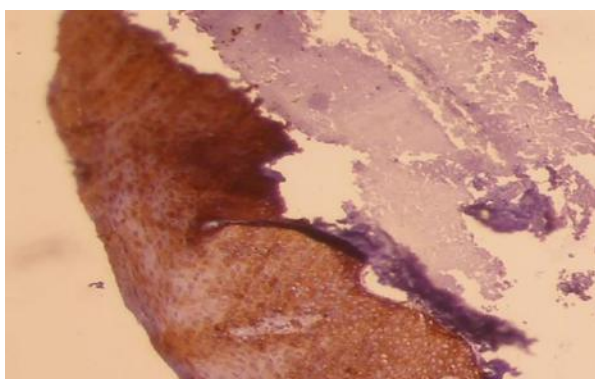
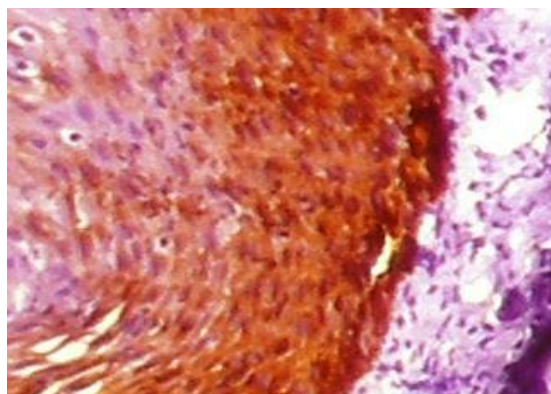
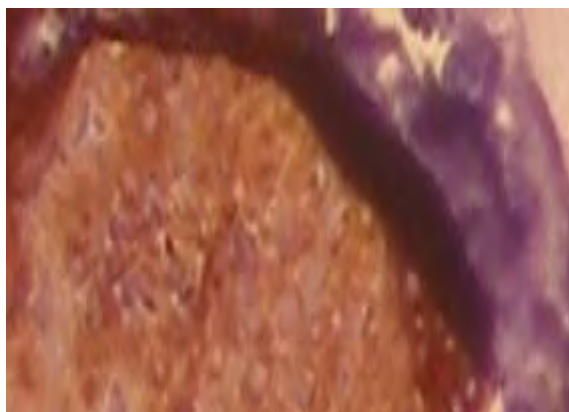
Dr Shan Nawaz Malik did his BDS and MDS in Oral and Maxillofacial pathology under Rajiv Gandhi university of health sciences ,Bangalore Karnataka, he worked as lecturer in Yenepoya university and university science Malaysia, presently he is pursuing his PhD, he has numerous national and international publications to his credit and have done presentations in national and international conferences, some of his research interest includes, Potentially malignant disorders, Immunohistochemical studies and Racial dimorphism among different populations depending on tooth size and morphology.

Histological staging of severity of OSF with CK19 Expression

Lesions/control	CK19 EXPRESSION				Total
	negative	Mild	moderate	Intense	
OSFgrade1 8	1(12.5%)	1(12.5%)	4(50%)	2(25%)	8(100%)
Osf grade2 14	0	9(64.2%)	3(21.4%)	2(14.2%)	14(100%)
Osf grade3 13	0	3(23%)	6(46.1%)	4(30.7%)	13(100%)
Total	1(2.8%)	13(37.1%)	13(37.1%)	8(22.8%)	35(100%)

TABLE 1: Histological staging of severity of OSF P-value= 0.136

INSTENSITY OF STAINING OF CK19 IN DIFFERENT GRADES

**GRAPH 1: INSTENSITY OF STAINING OF CK19****FIGURE 1: OSF GRADE 1 CK19 STAINING (10 x magnifications)****FIGURE 2: OSF GRADE 2 CK19 STAINING (10 x magnification)****FIGURE 3: OSF GRADE 3 CK19 STAINING (10 x magnification)**